

Lymph node cytology case study

Charlie

Patient: Charlie, 14-year-old, neutered male Yorkshire terrier

Presenting complaint: A firm swelling under the jaw was noticed by the client about 4 days prior to presentation. A decreased appetite was also reported.

Physical examination: Charlie was quiet, alert, and responsive. Heart rate 110 beats per minute; respiratory rate 20 per minute; temperature 102.2°F (39°C). Body condition score (BCS) 3/9; muscle condition score (MCS): moderate muscle loss. Moderate nuclear sclerosis was noted in both eyes. There was moderate periodontal disease. Enlarged (2.5–3 cm) and firm submandibular, prescapular, axillary, inguinal, and popliteal lymph nodes were found. Other examination findings were unremarkable.

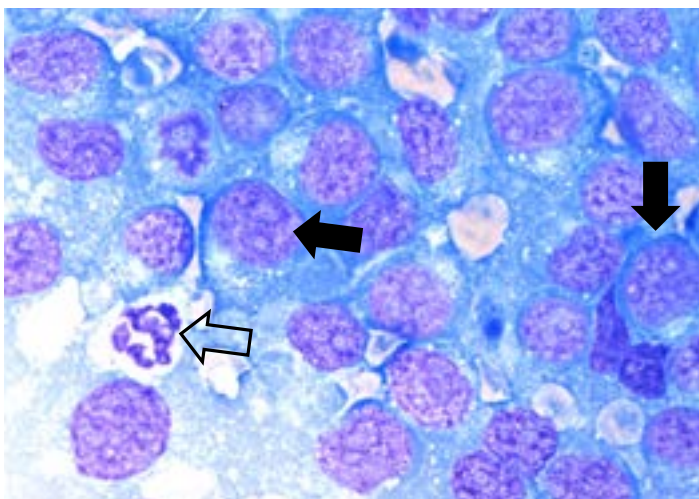


Diagnostic plan

Samples were collected for an IDEXX CBC-Select*, serum chemistry including an IDEXX SDMA* Test, total T₄, complete urinalysis, and Lab 4Dx* Plus Test. Fine needle aspirates were collected from the prescapular, axillary, inguinal, and popliteal lymph nodes, as well as the left mandibular lymph node. Slides were prepared from the aspirates and all samples were submitted to IDEXX Reference Laboratories.

Diagnostic review

- + CBC showed mild nonregenerative anemia as indicated by the absence of reticulocytosis. Additionally there was a mild neutrophilia, monocytosis, and eosinopenia.
- + The serum chemistry showed increased IDEXX SDMA, ALP, amylase, and lipase levels as well as decreased albumin.
- + The urinalysis and total T₄ were unremarkable, and the Lab 4Dx® Plus Test results for vector-borne disease were negative.
- + The decreased reticulocyte hemoglobin, nonregenerative anemia, mild neutrophilia, monocytosis, eosinopenia, and hypoalbuminemia collectively are nonspecific indicators of an inflammatory process.



Key: Intermediate to large lymphoid cells (solid arrows) with nuclei of similar size to a neutrophil (open arrow).

The pathologist's report on the fine needle aspirates shows that all the slides contain a similar cell population that is highly cellular, and the majority of the cells are intermediate to large lymphocytes. There is a high nucleus-to-cytoplasmic (N:C) ratio with eccentric oval to slightly irregular nuclei with finely stippled chromatin, multiple nucleoli, and a scant amount of deeply basophilic cytoplasm. Mitotic activity appears moderate. The cytologic findings are consistent with an intermediate to high-grade lymphoma.

Hematology

10/19/22 (Order Received)
10/19/22 3:38 PM (Last Updated)

TEST	RESULT	REFERENCE VALUE	
RBC	5.05	5.39 - 8.70 M/μL	L
Hematocrit	36.1	38.3 - 56.5 %	L
Hemoglobin	10.9	13.4 - 20.7 g/dL	L
MCV	71	59 - 76 fL	
MCH	21.6	21.9 - 26.1 pg	L
MCHC	30.2	32.6 - 39.2 g/dL	L
% Reticulocyte	0.5	%	
Reticulocytes	25	10 - 110 K/ μ L	
Reticulocyte Hemoglobin	24.2	24.5 - 31.8 pg	L
WBC	15.4	4.9 - 17.6 K/ μ L	
% Neutrophils	83.5	%	
% Lymphocytes	7.8	%	
% Monocytes	8.4	%	
% Eosinophils	0.1	%	
% Basophils	0.2	%	
Neutrophils	12.859	2.94 - 12.67 K/μL	H
Lymphocytes	1.201	1.06 - 4.95 K/ μ L	
Monocytes	1.294	0.13 - 1.15 K/μL	H
Eosinophils	0.015	0.07 - 1.49 K/μL	L
Basophils	0.031	0 - 0.1 K/ μ L	
Platelets	215	143 - 448 K/ μ L	

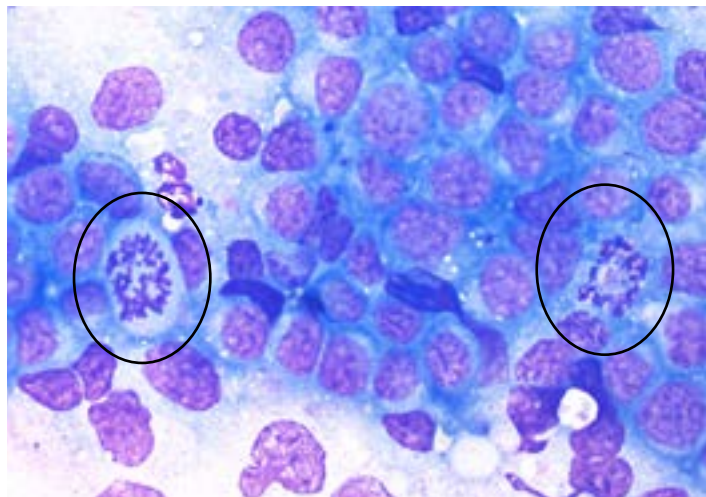
Chemistry

10/19/22 (Order Received)
10/19/22 3:38 PM (Last Updated)

TEST	RESULT	REFERENCE VALUE	
Glucose	80	63 - 114 mg/dL	
IDEXX SDMA	a 37	0 - 14 μg/dL	H
Creatinine	1.0	0.5 - 1.5 mg/dL	
BUN	27	9 - 31 mg/dL	
BUN: Creatinine Ratio	27.0		
Phosphorus	5.9	2.5 - 6.1 mg/dL	
Calcium	9.1	8.4 - 11.8 mg/dL	
Sodium	147	142 - 152 mmol/L	
Potassium	4.9	4.0 - 5.4 mmol/L	
Na: K Ratio	30	28 - 37	
Chloride	113	108 - 119 mmol/L	
TCO2 (Bicarbonate)	20	13 - 27 mmol/L	
Anion Gap	19	11 - 26 mmol/L	
Total Protein	6.2	5.5 - 7.5 g/dL	
Albumin	2.5	2.7 - 3.9 g/dL	L
Globulin	3.7	2.4 - 4.0 g/dL	
Albumin: Globulin Ratio	0.7	0.7 - 1.5	
ALT	53	18 - 121 U/L	
AST	44	16 - 55 U/L	
ALP	511	5 - 160 U/L	H
GGT	2	0 - 13 U/L	
Bilirubin - Total	0.1	0.0 - 0.3 mg/dL	
Bilirubin - Unconjugated	0.0	0.0 - 0.2 mg/dL	
Bilirubin - Conjugated	<0.1	0.0 - 0.1 mg/dL	
Cholesterol	199	131 - 345 mg/dL	
Amylase	1,978	337 - 1,469 U/L	H
Lipase	b 396	0 - 250 U/L	H
Creatine Kinase	164	10 - 200 U/L	

CBC reveals mild nonregenerative anemia and suggests inflammation.

Blood chemistry panel reveals elevated SDMA, decreased albumin, increased ALP, and increased amylase and lipase. VetConnect PLUS provides differential diagnoses for these parameters.



Key: Mitotic figures circled

Diagnosis

Charlie was diagnosed with multicentric large cell lymphoma, a catch-all term that encompasses a diverse group of cancers derived from different lymphocyte subtypes with variable clinical outcomes. Large cell lymphoma typically has an aggressive biologic behavior and rapid clinical course when left untreated, but it usually responds to chemotherapy.

More than 80% of canine lymphomas are the multicentric form (i.e., generalized lymphadenopathy), while less prevalent forms involve extranodal sites and/or are restricted to specific organs. The clinical presentation, extent, and stage of disease—along with other factors—will influence the prognosis and treatment approach for each patient.

Additional testing

To evaluate for presence of lymphoma in extranodal locations, ultrasound could be considered.

Additional lymphoma testing options are available, whether to help guide patient prognosis and treatment (e.g., B-cell versus T-cell distinction) or to further confirm and subtype/classify the lymphoma beyond its cell size and morphologic characterization.¹

IDEXX provides an extensive menu of diagnostic options for evaluation of your patients. Additionally, our Medical Consulting Service is available to provide insight on patient management and treatment.

References

1. Vail DM, Pinkerton M, Young KM. Hematopoietic tumors. In: *Withrow & MacEwen's Small Animal Clinical Oncology*, 6th ed. St Louis, MO: Elsevier; 2020.

© 2023 IDEXX Laboratories, Inc. All rights reserved. • 09-2690457-00 • All ®/TM marks are owned by IDEXX Laboratories, Inc. or its affiliates in the United States and/or other countries. The IDEXX Privacy Policy is available at [idexx.com](https://www.idexx.com).

- + PARR assay (PCR for Antigen Receptor Rearrangement) can use the already submitted and stained slides to assess for lymphocyte genetic clonality. It can help confirm lymphoma and usually provides a B-cell versus T-cell distinction. The PARR test performed through IDEXX Reference Laboratories has an overall 93% sensitivity and 94% specificity for detecting lymphoma in dogs (CSU Clinical Hematopathology Laboratory, 2022). A negative PARR result does not rule out lymphoma. Test code 1933 in US, LYMPCR in Canada.
- + Flow cytometry immunophenotyping of fresh lymph node aspirates placed in a fluid medium can help subtype/classify lymphoma and might distinguish some indolent forms from more aggressive lymphoma variants. Special collection and instructions are required. This test requires live cells for evaluation, so collecting samples prior to chemotherapy or prednisone therapy and submitting samples earlier in the week may help ensure cell viability for testing.
- + Lymph node biopsy and histopathology with immunohistochemistry (IHC) remains the gold standard for subtype classification and grading of lymphoma. Excision of a lymph node, including its capsule, or at least a large wedge biopsy of lymph node (or other appropriate organ) is advised over needle-core biopsies.
- + Immunocytochemistry (ICC) is a valuable ancillary testing option that pathologists may recommend to provide a limited B/T cell immunophenotype for cases interpreted as cytologic lymphoma. ICC may also be helpful to clarify the cell lineage in ambiguous cases.

Treatment and outcome

The client declined the recommendations for additional diagnostic testing. They agreed to treat Charlie with prednisone until the patient's quality of life declined, at which point humane euthanasia would be chosen.

Use IDEXX Cytology to submit multiple lymph node aspirates under one submission code. IDEXX also offers ancillary tests such as PARR, flow cytometry, and ICC/IHC to provide a complete clinical picture.